

TO SUBSTANTIATION OF THE LIST OF HAZARDOUS HIGHLY TOXIC CHEMICALS THAT ARE SUBJECT TO SPECIAL CONTROL REGARDING HANDLING, STORAGE, USE AND DISPOSAL

Part III (bipyridyl herbicides paraquat and diquat)

M. Prodanchuk¹, G. Balan¹, O. Kravchuk¹, P. Zhminko¹, I. Maksymchuk², N. Chermnykh¹

¹LI Medved's Research Centre of Preventive Toxicology, Food and Chemical Safety, Ministry of Health, Ukraine (State Enterprise), Kyiv, Ukraine

²National Police of Ukraine, Kyiv, Ukraine

ABSTRACT. The Aim of the Research. To identify a group of highly toxic chemicals which over the past decades are most often used in deliberate criminal and suicidal incidents, sabotage, and terrorist act; the handling, storage, use and disposal of which must be especially carefully monitored by law enforcement agencies. In this part of the article bipyridyl herbicides paraquat and diquat are considered.

Materials and Methods. An analytical review of scientific publications was carried out using the abstract databases of scientific libraries Pub Med, Medline and text databases of scientific publishing houses Elsevier, Pub Med, Central, BMJ group as well as other VIP databases. Methods of systemic, comparative, and content analysis were used.

Results and Conclusions. Analytical review of literature data and research carried out at the State Enterprise Scientific Centre of Preventive Toxicology, Food and Chemical Safety named after Academician L.I. Medved of the Ministry of Health of Ukraine, showed that highly toxic bipyridyl herbicides paraquat and diquat can pose a threat to human life and health. Recently, in particular for more than a quarter of a century, they have become a real weapon in the hands of criminals, delinquents, and terrorists all over the world. Suicidal incidents, which also take place along with intentional criminal, terrorist, and sabotage acts, should not be concealed. Based on the analysis of the toxicity, clinical and morphological expression of intoxication when exposed to these chemicals, considering various routes of entry into the body, the need to include them in the List of hazardous highly toxic chemicals, the handling, storage, use, and disposal of which require stricter control of law enforcement agencies, is justified.

Key Words: bipyridyl herbicides, paraquat, diquat, health risk, acute poisoning.

The Aim of the Research. To identify a group of highly toxic chemicals which over the past decades are most often used in deliberate criminal and suicidal incidents, sabotage, and terrorist act; the handling, storage, use and disposal of which must be especially carefully monitored by law enforcement agencies. In this part of the article bipyridyl herbicides paraquat and diquat are considered.

Materials and Methods. An analytical review of scientific publications was carried out using the abstract databases of scientific libraries Pub Med, Medline and text databases of scientific publishing houses Elsevier, Pub Med, Central, BMJ group as well as other VIP databases. Methods of systemic, comparative, and content analysis were used.

Results and Conclusions

Paraquat and diquat. Over the past 20-30 years, in many regions of the world, especially in the countries of the Asia-Pacific region, the main cause of deliberate criminal and suicidal

poisoning with a very high mortality rate (>50%) are bipyridyl herbicides – paraquat and diquat [1-4]. Most often, paraquat poisoning is recorded [1-4]. Death from poisoning with this herbicide has been a major clinical public health problem in agricultural areas of Southwest Asia in recent decades [5-8]. Especially in China, Taiwan and India, cases of paraquat poisoning have a high mortality rate, they reach 68%, and have signs of an epidemic nature [5-7]. A number of authors analysed the clinical manifestations and consequences of acute poisoning with paraquat as well as the methods of treatment used. In their field of vision there was a significant number of victims, including 9300 patients [9], and 604 patients in Sri Lanka [3, 11], 1811 patients in Taiwan, 298 patients [12] and 62 patients in China [26].

Criminal and suicidal paraquat poisoning continues to kill humanity in all countries, especially, as noted above, in the agricultural regions of Southwest Asia [9, 13-15].

Poisoning by this pesticide is a problem not only in this region [15]. In the 1980s and 1990s, in Trinidad and Tobago, paraquat was used in 63% of all suicide cases, in particular in southern Trinidad in 76% within one year from 1996 to 1997 [16], in Samoa in 70% from 1979 to 2000 [17]. From 1945 to 1989, it was responsible for 56% of all acute fatal pesticide poisoning in England and Wales [18, 19]. According to the National Association of Poison Control Centres of the USA in 2008, paraquat caused more deaths than any other pesticide [20]. About 10 years ago, due to its high toxicity, significant mortality in acute poisoning and the lack of effective methods of treatment, paraquat was banned in a number of European countries and in Sri Lanka. But its production and use in agriculture continues in most countries of Southwest Asia, and it is also widely distributed by smuggling and through advertisements on internet sites.

The herbicide paraquat (1,1-dimethyl-4,4-dipyridyl chloride) is the most important of the 5 bipyridyl herbicides, which include paraquat, diquat, chlormequat, dibenzoquat and morfamquat. Paraquat and diquat were most widely used in agriculture as herbicides and desiccants, and in many countries this process continues to this day [1-4]. Until recently, paraquat has dominated at the global herbicide market, second only to glyphosate [26]. It is marketed in about 130 countries as a fast acting, nonselective herbicide, defoliant, and desiccant that destroys the green tissue of a plant by contacting and migrating inside of it [126]. Due to its high toxicity, the European Union excluded paraquat from its market in 2007. This pesticide is also banned in French Guiana (2010), Sri Lanka (2010) and South Korea (2012). In other southwestern countries, paraquat is still used as a desiccant (gramoxone, dextran X, esgram, PP 148, etc.). Diquat and more than 30 preparations based on it are approved for use in Ukraine as a desiccant for sunflower, pea, alfalfa, and other agricultural crops. The toxicity of diquat, although 5–6 times lower than that of paraquat, however, the mortality rate in case of oral poisoning reaches 40–50% [1-4]. That is why, as we reported in previous works [24], we consider it expedient to strengthen control over the smuggling of paraquat into the country, as well as over the storage and use of officially permitted diquat.

Paraquat is highly toxic to humans and most animals. It is marketed mainly in the form of an emulsified concentrate 200 g/l (Gramoxone). With oral deliberate criminal, suicidal or accidental use of concentrated solutions, the lethal dose of paraquat is approximately 3–4 mg/kg, LD₅₀ – 25–50 mg/kg. Inhalation or percutaneous action of 5–30% solutions in violation of hygienic regulations causes acute poisoning with damage to the mucous membranes of the eyes, nose, and mouth, with the appearance of cramps in the eyes, hyperaemia, lacrimation, runny nose, burning and sore throat, hacking cough [1-10]. Oral administration of large doses of paraquat is also accompanied by nausea, vomiting, a burning sensation in the mouth, especially in the tongue, behind the sternum along the oesophagus and in the epigastrium. With instant poisoning death occurs within 30–40 minutes or several hours from cardiopulmonary failure. With an average and especially severe form of poisoning, shortness of breath appears next to the above symptoms, which increases over the next days, depending on the dose of paraquat received, death occurs after a few days or weeks. Mortality also depends mainly on the dose received and reaches 25–75% [1-9, 16-19, 25, 26]. A few hours or days after using the paraquat solution, the victim usually develops multiple organ pathology with neurotoxic effects, kidney damage with the rapid formation of acute renal failure with an increase in creatinine levels up to 600–800 mmol/l. Lesions of the gastrointestinal tract are accompanied by ulcers, haemorrhages and edema of the tongue (Fig. 1) [8], mucous membranes of the mouth, pharynx, oesophagus, stomach, and intestines. At the same time, liver damage with pronounced cytolytic syndrome and a decrease in synthetic function is increasing.

The most pronounced changes with the development of infiltrative and interstitial disorders, alveolitis, edema and fibrosis, which develop rapidly, are observed in the lungs, and often lead to death. Among all the toxic effects, it is the lungs toxic effects that are dangerous, characterized by progressive damage to the lung parenchyma, hyperaemia, atelectasis, edema, foci of haemorrhages and necrosis. X-ray and CT revealed infiltrative changes with the areas of atelectasis, diffuse alveolar shadows and bilateral interstitial and intra-alveolar pulmonary fibrosis (Fig. 2, 3) [8].

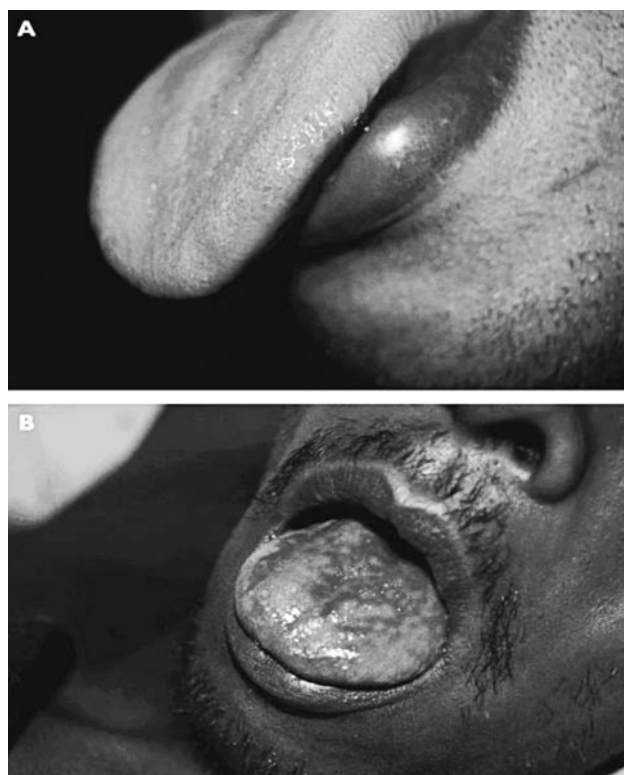

Fig. 1. A) early involvement of the tongue 24 hours after exposure to paraquat; B) late lesions of the tongue with large ulcers 2 weeks after exposure to paraquat (I.B. Gawarammana, N.A. Buckley, 2011) [8].

The mechanism of the toxic action of bipyridyl herbicides, especially paraquat, is due to their super-high prooxidant activity. Superoxide radicals, which are formed, disrupt the structure of the lipid matrix of the cell membrane as well as of mitochondria and cause hypoxia [26-29, 32-35]. Development and energy deficit of pronounced early (after 4–7 hours) destructive changes caused by paraquat in alveolar epithelial cells i.e. type I and especially type II pneumocytes, happen due to the high affinity of this herbicide to these pneumocytes.

In our Centre (formerly the All-Union Scientific Research Institute of Hygiene and Toxicology of Pesticides, Polymer and Plastics), back in 1972, V.N. Makovsky completed the dissertation “Toxicological studies of bipyridyl herbicides (diquat and paraquat)” [15]. The author showed that paraquat is a potent poisonous substance for most species of warm-blooded animals (LD₅₀ for guinea pigs is 42 mg/kg, for white mice is 56 mg/kg, for white rats is 128 mg/kg), while diquat is highly toxic (LD₅₀ for these animals is 100, 86 and

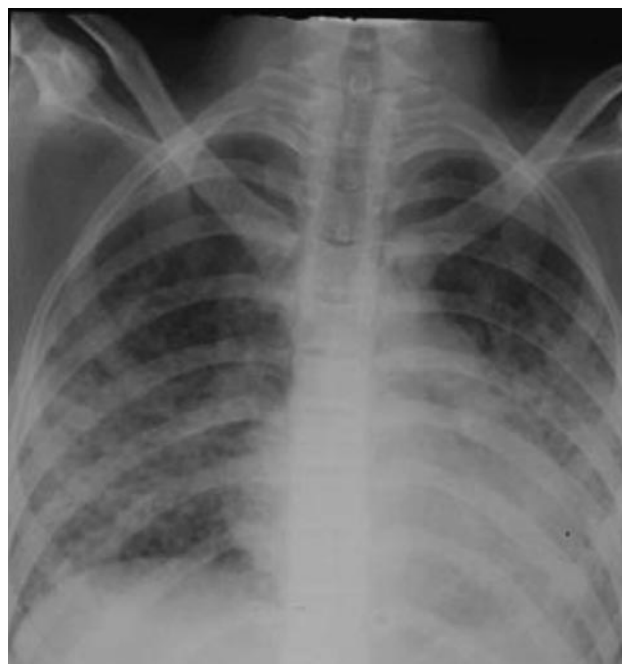

Fig. 2. Chest X-ray of the patient showing diffuse alveolar lesions 7 days after exposure to paraquat (I.B. Gawarammana, N.A. Buckley, 2011) [8].

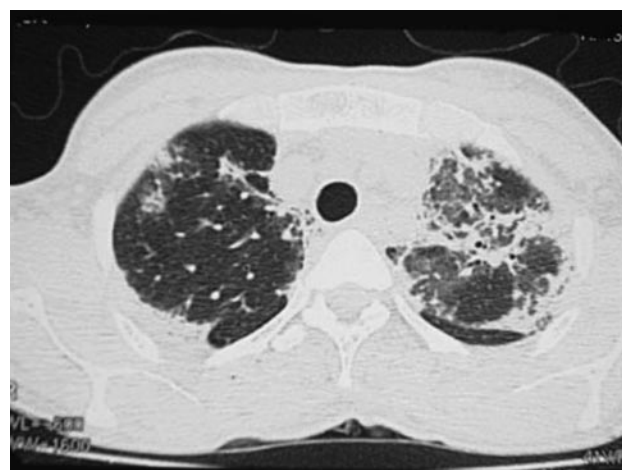


Fig. 3. CT scan of the patient's chest, which demonstrates bilateral pulmonary fibrosis 11 days after exposure to paraquat (I.B. Gawarammana, N.A. Buckley, 2011) [8].

210 mg/kg, respectively). Moreover, both herbicides have pronounced skin-resorptive toxicity: LD₅₀ of paraquat for rats is 350 mg/kg, for guinea pigs is 318 mg/kg, LD₅₀ of diquat is 650 and 400 mg/kg, respectively. It has also been shown that they have pronounced toxicity when inhaled into the body. CL₅₀ of paraquat for rats is 6 mg/m³, for guinea pigs is 4 mg/m³, CL₅₀ of diquat is 35 and 38 mg/m³, respectively. The prooxidant activity of these herbicides, as well as hemodynamic, dystrophic, and necrotic disorders in the brain, liver, kidneys, and especially in the lungs, has been proven.

Using paraquat as a weed desiccant, it was found in large quantities in plants (>200 mg/kg dry weight of grass), and its slow disintegration was also established. After the use of pre-harvest desiccants, the concentrations of these herbicides were increased in potato tubers. Due to the revealed pronounced toxicity and significant resistance in environmental objects, the scientist V.N. Makovsky back in 1972 substantiated the inexpediency of using paraquat in agriculture in the USSR and insisted on the limited use of diquat (only as a desiccant). In Ukraine, paraquat has never been registered or officially used, but now it is available for sale on Internet sites. This is a very dangerous signal.

Several enzyme systems are involved in the metabolism of paraquat (NADP-F-Cytochrome P450 reductase, Xanthine oxidase, NADH: ubiquinone oxidoreductase and NO-synthase) [14, 27, 32, 34, 35]. Its metabolism through these systems contributes to the formation of the monocationic paraquat radical (PQ^+). Within the cells of the body, PQ^+ is rapidly oxidized to PQ^{2+} while superoxide (PQ_2^-) is formed. PQ_2^- acts as an electron acceptor, and NADP as an electron donor in this reaction, which leads to the additional formation of a hydroxyl free radical (HO) [8, 14, 26-29]. In the presence of iron, this leads to the formation of peroxyxynitrite ($ONOO^-$), which is a very strong oxidizing agent and an intermediate nitrosating agent. The generation of highly effective forms of oxygen and nitrites leads to the development of toxic destructive disorders in most organs, especially in the lungs, due to the high selective accumulation of paraquat in type II pneumocytes and less in type I pneumocytes. Electrophilic free radicals, in turn, extract free hydrogen atoms from polyunsaturated fatty acids, causing progressive activation of lipid peroxidation (LPO), which disrupts the function of cell and mitochondrial membranes and activates apoptosis. This is facilitated by proteasome dysfunction that occurs in cells [26]. It is believed that LPO activation is a key initial pathophysiological process in the cascade of destructive disorders in paraquat poisoning [26-29, 32-37]. Simultaneously with the activation of LPO, a Ca^{2+} -dependent increase in the permeability of the inner mitochondrial membrane develops, which leads to its depolarization, separation and swelling of the matrix. Along with

this, reactive oxygen species activate a nuclear factor in cells – NF- κ B (nuclear factor kappa-light-chain-enhancer of activated B cells), which moves to the nucleus, binds to promoter sites, induces target genes that cause transcription of pro-inflammatory proteins i.e. enzymes, cytokines, and chemokines (cytokine storm). This leads to platelet aggregation, impaired microcirculation, and the attraction of inflammatory cells. Simultaneously, the production of reactive oxygen species and the activation of NF- κ B lead to nuclear condensation and DNA fragmentation, disrupt cellular enzymatic and signalling pathways, causing disruption of homeostasis and progressive activation of apoptosis with the formation of foci of necrosis in various organs, especially in the lungs, kidneys, and heart muscle.

It has been shown that paraquat is a neurotoxin i.e. treatment of nerve cells with it both in vitro and in vivo leads to a decrease in the expression of Mfn1 (mitofusin 1) and Mfn2 (mitofusin 2) proteins, which is accompanied by mitochondrial fragmentation and their dysfunction [30]. The significance of the nuclear factor 2 of erythroid origin – Nrf2 (nuclear factor, erythroid 2), as well as of a number of micro-RNAs in the neurotoxic effects of paraquat, in particular in terms of the function of micro-RNA – miR-380-3p, which is violated by paraquat, was revealed. It was found that Nrf2, a regulated inhibition of miR-380-3p cell proliferation and an increase in paraquat neurotoxicity, is associated with blocking the translation of messenger ribonucleic acid transcription factor SP3 [31]. Its role in the suppression of calmodulin and inhibitor 1 of cyclin-dependent kinase (p21) was also noted.

It was experimentally established that when paraquat acts on microglial cells of BV_2 mice, their activation occurs, which is accompanied by an intense increase in the expression of mRNA, inflammatory cytokines – tumour necrosis factor α , interleukin- 1β and interleukin-6 [38]. In the presence of paraquat, there is also an increase in the expression of heat shock protein 60 (HSP) and toll-like receptor 4 (TLR4), as well as of nuclear factor κ B-p65 (kappa-B p65), activated protein 1, c-fos proto-oncogene and c-jun proto-oncogene. This allowed the authors to conclude that paraquat activates microglial cells and increases the expression and secretion of proinflammatory cytokines with the participa-

tion of the HSP/TLR4 signalling cascade, which determine the formation of intense inflammatory reactions [38]. Thus, there is an opinion that the formation of neurotoxic effects of paraquat, as well as damage to the lungs [39], is not only a powerful activation of oxidative stress, intense expression of a cascade of proinflammatory factors in the form of a cytokine storm, which causes impaired microcirculation and the formation of hypoxia, but also pronounced autophagic dysfunction with activation of apoptosis.

Apparently, due to the selective tropism of paraquat to pneumocytes and its high accumulation in them, the primary target of toxicity in the lungs is the alveolar epithelium, which leads to the development of acute alveolitis and pulmonary edema [1-8]. After this initial phase, after 2–4 days, the proliferative phase begins, when the alveolar space is filled with mononuclear profibroblasts, which mature into fibroblasts within a few days or weeks. This stage is followed by pulmonary fibrosis. Due to severe hypoxia and rapidly progressive pulmonary fibrosis, patients die within 3–5 weeks [1-9, 40, 41]. Pulmonary fibrosis usually develops a few days or several weeks after taking paraquat, depending on the dose received. At autopsy in 8 cases of paraquat poisoning with a lethal outcome in areas of pulmonary fibrosis and in areas of its absence, the expression of autophagy biomarkers – beclin-1, associated with microtubules of light chain protein (LC3) and p62 protein was investigated [39]. The relationship between pulmonary fibrosis and the expression of autophagy markers has been established. The authors concluded that autophagic dysfunction is the basis for pulmonary fibrogenesis in paraquat poisoning. It was also found that when rats are exposed to paraquat, fibrosis is manifested by an increased content of hydroxyproline, oxidative stress, and increased expression of profibrotic genes [40]. At the same time, the joint administration of pirfenidone and prednisolone for 14 days reduced the content of hydroxyproline, TGF- β 1 (transforming growth factor beta 1) and TNF- α (tumour necrosis factor- α) in the lungs. Their action also contributed to a decrease in the increased level of pro-inflammatory metalloproteinases – MMP-2 (matrix metalloproteinase-2) and TIMP1 (tissue inhibitor of matrix metalloproteinase-1). On a model of lung damage in mice, caused by

paraquat at a dose of 20 mg/kg it was found the development of pulmonary edema and fibrosis, infiltration of lung tissue by macrophages, an increase in the concentration of pro-inflammatory factors TGF- β 1 and hydroxyproline in the lung tissue which was accompanied by disorder in expression of genes associated with fibrogenesis and the production of active forms of O₂, as well as such pro-inflammatory and profibrogenic factors as TGF- β 1, α -SMA (alpha-smooth muscle actin), collagen Ia and IV, NOX1 (NADPH oxidase 1), NOX4 (NADPH oxidase 4), inducible NO synthase, and GPX1 (glutathione peroxidase 1) [41]. When mice were given paraquat, pirfenidone was simultaneously administered at a dose of 100 and 200 mg/kg for 28 days. Signs of poisoning were accompanied by a decrease in pulmonary edema and fibrosis, in part due to inhibition of inflammation and oxidative stress, as well as due to a decrease in the expression of genes encoding the synthesis of profibrotic cytokines and prooxidant and antioxidant enzymatic systems associated with the production of active forms of O₂. These facts need to be considered when developing treatment methods.

Toxic kidney damage when exposed to paraquat in mice is characterized by pronounced vacuolization of the cells of the proximal renal tubules with the development of foci of necrosis [42]. In patients with poisoning, there is an increase in acute renal failure with an increase in serum creatinine levels up to 700–800 mmol/l [8, 43], as well as cystatin and NGAL (neutrophil gelatinase-associated lipocalin) [43]. Additional tests to assess the severity and predict the consequences of acute renal failure were compiled and substantiated. Thus, to assess the severity and predict the results, a number of laboratory tests are justified when examining 120 patients with acute paraquat poisoning [45]. A mild course of intoxication was in 28 of them, moderate in 52, severe in 40. The authors report the possibility of using elevated serum and urine levels of presepsin (soluble subtype CD14) and lipocalin, which is associated with gelatinase of neutrophils, for predicting death and as markers of acute renal failure [45].

Already on the first day, with paraquat poisoning, toxic liver damage appears with an increase in cytolytic syndrome. Patients develop pain in the right hypochondrium, yellow-

ness of the skin, an increase in the size of the liver, for which degradation of the endoplasmic reticulum and damage to the mitochondria of hepatocytes become characteristic [44]. At the same time, toxic damage to the gastrointestinal tract with hyperaemia and ulcers in the tongue ("paraquat tongue", Fig. 2), pharynx, oesophagus, stomach, and intestines is observed, with bleeding, bloody vomiting, and bloody diarrhoea with moderate and severe intoxication. This can lead to perforation, mediastinitis, or mediastinal emphysema [8]. For the rapid diagnosis of acute paraquat poisoning, a dithionite test is proposed: 0.1 g of sodium bicarbonate (NaHCO_3) and 0.1 g of sodium dithionate ($\text{Na}_2\text{S}_2\text{O}_4 \cdot 2\text{H}_2\text{O}$) are added to 5 ml of urine or gastric lavage samples, which are analysed. In the presence of paraquat, a blue colouration of the sample is formed. The method is qualitative, it allows you to determine 20-50 mg/ml of a substance in a test tube.

An unfavourable consequence of paraquat poisoning is predicted when taking large doses of a concentrate or solutions with a significant amount of it orally, if a high content of the herbicide in blood plasma and urine is determined, as well as in the case of early development of multiple organ failure and severe alveolitis [1-9, 18, 40]. Analysing 130 clinical observations of acute paraquat poisoning, of which 35 (26,8%) were fatal, it was found that an important indicator for such a prognosis is also the severity of immunity disorders, including changes in the number of CD4^+ and CD8^+ lymphocytes [46].

A number of experimental studies have found that paraquat causes endocrine disruptor effects. Its effect on rats (0,5, 2 and 8 mg/kg per day), significantly reduces the serum testosterone content (2 and 8 mg/kg), slows down the regeneration of Leydig stem cells in the testes of adult rats and promotes the formation of oxidative stress with high generation of reactive oxygen species [47]. It has also been shown that paraquat reduces the activity of estrogen receptors, which leads to the generation of amyloid beta proteins and hyperphosphorylation of Tau proteins, as well as leads to the formation of oxidative stress [48].

The provision of medical care for poisoning with paraquat and diquat should be immediate: rinsing the eyes and mouth with running water, forced vomiting and gastric lavage with the addition of intestinal adsorbents (fuller's earth,

bentonite, activated carbon, etc.), followed by the appointment of strong laxatives (10% mannitol, 20% magnesium sulphate, etc.) and means for forced diuresis (Lasix, Furosemide, etc.). It should be noted that there is no specific antidote against these herbicides. It is very important in the first hours after poisoning to use efferent methods of treatment (hemoperfusion, hemosorption and haemodialysis) to remove absorbed paraquat or diquat from the blood. For the treatment of acute poisoning with paraquat or diquat, a variety of treatment methods have been proposed, mainly with the inclusion of anti-inflammatory immunosuppressive agents (steroid hormones) or their combinations with cytostatic and antioxidants [8-14, 22-25, 40, 41, 49].

A graphic representation of the main mechanisms of paraquat toxicity inside a pneumocyte with subsequent entry into the blood and exposure to the body is shown in Fig 4. with an indication of the formation of free radicals (OHOO^\cdot , HO^\cdot) of oxidative stress with the subsequent development of tissue lesions. It was shown how reactive oxygen species activate the factor NF-kB in cells, which, being transformed into the nuclear factor NF-kB, moves into the nucleus, and induces the expression of target genes which cause transcription of pro-inflammatory proteins, platelet aggregation and the whole complex of destructive processes in the body. At the same time, the targets of potential therapy (intestinal adsorbents, haemodialysis, salicylates, antioxidants, hormones, cytostatic) are indicated [8].

Unfortunately, the proposed methods of treatment are not effective enough; when exposed to large doses of paraquat, mortality reaches 50–78% [1-14]. When the level of paraquat in the blood in patients in the first 2–4 hours after poisoning is higher than 2–3 mg/l it means 100% lethal outcome [50], while in case of diquat the lethal outcome is 50% when ingested 300–500 ml of 20% solution [22-23].

Thus, due to the pronounced toxicity, significant stability of paraquat in the environment, considering its wide availability through numerous advertisements for wholesale and retail sales on Internet sites, it is necessary to strengthen control and criminal liability for illegal traffic and use of it in Ukraine.

Diquat has a fairly high toxicity. In Ukraine, it is allowed to use more than 30 diquat-con-

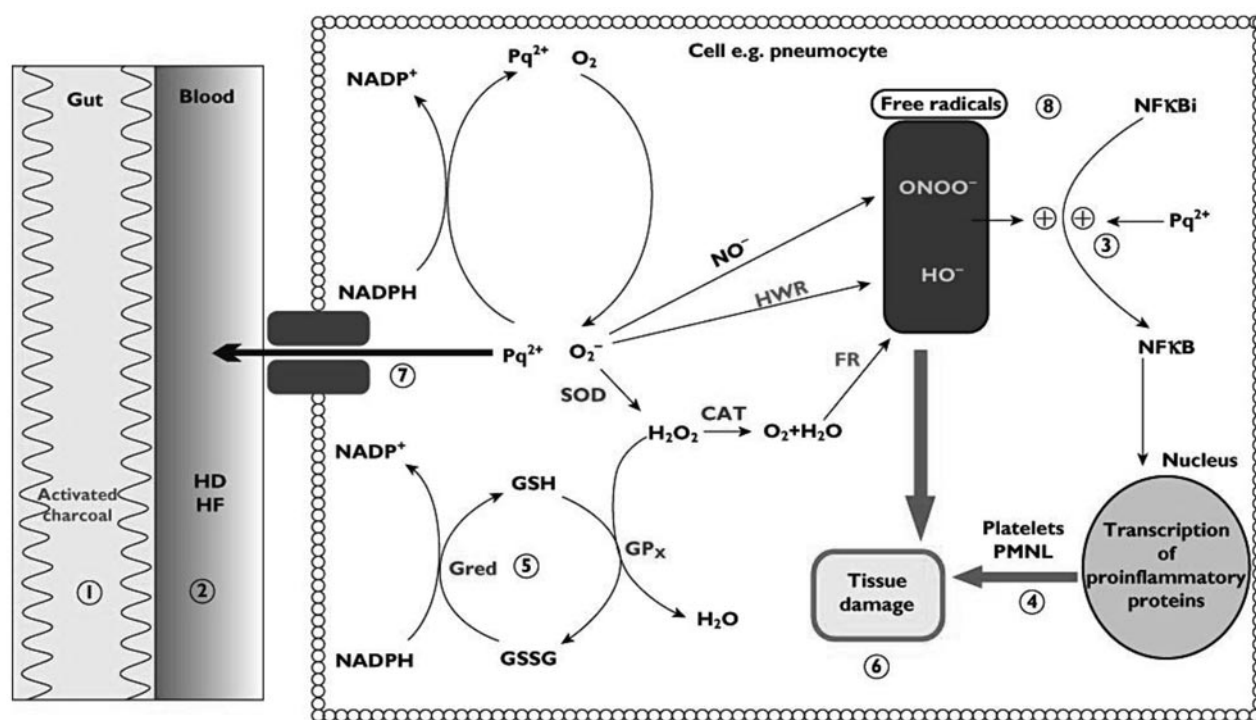


Fig. 4. Graphical representation of paraquat toxicity within pneumocytes and potential targets for antidote therapy: SOD (superoxide dismutase) CAT (catalase), Gred (glutathione reductase) Gpx (glutathione peroxidase) FR (Fenton reaction) HWR (Haber-Weiss reaction). 1–8 are potential sites for action of available treatments. 1. Activated carbon and Fuller’s earth; 2. Haemodialysis; 3, 4, 6. Salicylates; 5 and 8. N-acetylcysteine; 7. Induction of glycoprotein P: dexamethasone; 4. Immunosuppression (I.B. Gawarammana, N.A. Buckley, 2011) [8].

taining desiccants, of which 26 are used by the aerial method. Therefore, it is necessary to strengthen control over their storage, use and disposal. We consider it expedient to replace

diquat-containing preparations with less hazardous desiccants, as well as to limit their use as herbicides and desiccants in vegetable crops.

REFERENCES

- Jeyaratnam J. Acute pesticide poisoning: a major global health problem. *World Health Stat Q.* 1990;43:139–44.
- Eddleston M, Phsiisps MR, Self poisoning with pesticides. *BMG.* 2004;328:42–4.
- Gunnell D, Eddleston M, Phillips MR, et al. The global distribution of fatal pesticide self-poisoning: systematic review. *BMC Public Health.* 2007;7:357–9.
- Dawson AH, Eddleston M, Senarathna L, et al. Acute human lethal toxicity of agricultural pesticides: a prospective cohort study. *PloS Med.* 2010;7:e1000357.
- Yin Y, Guo X, Zhang SL, et al. Analysis of paraquat intoxication epidemic (2002–2011) within China. *Biomed Environ Sci.* 2013;26:509–12.
- Patel V, Ramasundarahettige C, Vijayakumar L, et al. Suicide mortality in India: a nationally representative survey. *Lancet.* 2012;379:2343–51.
- Chang SS, Lu TH, Eddleston M, et al. Factors associated with the decline in suicide by pesticide poisoning in Taiwan: a time trend analysis, 1987–2010. *Clin Toxicol.* 2012;50:471–80.
- Gawarammana IB, Buckley NA. Medical management of paraquat ingestion. *Br J Clin Pharmacol.* 2011;72:745–57. DOI:10.1111/j.1365-2125.2011.04026.x.
- Gawarammana IB, Buckley NA, Mohamed F, Nazer K, et al. High-dose immunosuppression to prevent death after paraquat self-poisoning – a randomized controlled trial. *Clin Toxicol.* 2017. DOI:org/10.1080/15563650.2017.1394465.
- Senarathna I, Eddleston M, Wilks MF, et al. Prediction of outcome after paraquat poisoning by measurement of the plasma paraquat concentration. *QJM.* 2009;102:251–259.
- Li LR, Sydenham E, Chaudhary B, et al. Glucocorticoid with cyclophosphamide for paraquat-induced lung fibrosis. *Cochrane Database Syst Rev.* 2014;8:CD008084.
- Wu WP, Lai MN, Lin CN, et al. Addition of immunosuppressive treatment to hemoperfusion is associated with improved survival after paraquat poisoning: a nationwide study. *PloS One.* 2014;9:e87568.
- Ghorbani A, Masoumi K, Forouzan A, et al. Effect of pulse therapy with glucocorticoids and cyclophosphamide in patients with paraquat poisoning. *Hong Kong J Emerg Med.* 2015;22:235–40.
- Parakvat i dikvat. *Gigiyenicheskiye kriterii sostoyaniya okruzhayushchey sredy. Sovmestnoye izdaniye Programmy OON po okruzhayushchey srede. Mezhdunarodnoy organizatsii truda i VOZ. Zheneva; 1989. 158 s.*

15. Makovskiy VN. Toksikologo-gigiyenicheskoye issledovaniye dipiridilovykh gerbitsidov (dikvata i parakvata) [dissertatsiya] Kiyev; 1972.
16. Hutchinson G, Daisley H, Simeon D, Simmonds V, Shetty M, Lynn D. High rates of paraquat-induced suicide in southern Trinidad. *Suicide Life Threat Behav.* 1999;29:186–91.
17. Bourke T. Suicide in Samoa. *Pac Health Dialog.* 2001;8:213–9.
18. Dargan P, Shiew C, Gawarammana I, Jones A. Paraquat poisoning: caution in interpreting prognosis based on plasma paraquat concentration. *Clin Toxicol.* 2006;44:762.
19. Casey P, Vale JA. Deaths from pesticide poisoning in England and Wales: 1945-1989. *Hum Exp Toxicol.* 1994;13:95–101.
20. Bronstein AC, Spyker DA, Cantilena LR Jr, Green JL, Rumack BH, Giffin SL. 2008 annual report of the American Association of Poison Control Centers National Poison Data System (NPDS): 26th annual report. *Clin Toxicol. (Phila)* 2009;47:911–1084.
21. Wilks MF, Tomenson JA, Fernando R, Ariyananda PL, Berry DJ, Buckley NA, et al. Formulation changes and time trends in outcome following paraquat ingestion in Sri Lanka. *Clin Toxicol. (Phila)* 2011;49:21–8.
22. Wanhalder R, Coraldyn J, De Reuck F. Diquat intoxication. *Am J Med* 1981;70:1267–71.
23. McCarthy LG, Speth CP. Diquat intoxication. *Ann Emerg Med* 1983;12:394–6.
24. Balan GM, Prodanchuk NG, Bubalo NN, Babich VA. Sostoyaniye i perspektivy antidotnoy terapii ostrykh otravleniy pestitsidami. Suchasni problemi toksikologii. kharchovoi ta khimichnoi bezpeki. 2015;1–2:67–76.
25. Elenga N, Merlin C, Le Guern R, Kom-Tchamen R, et al. Clinical features and prognosis of paraquat poisoning in French Guiana. *Med.* 2018;97:15(e9621).
26. Yang W, Tiffany-Castiglioni E. The bipyridyl herbicide paraquat induces proteasome dysfunction in human neuroblastoma SH-SY5Y cells. *J Toxicol. Environ Health A.* 2007;70:1849–57.
27. Castello PR, Drechsel DA, Patel M. Mitochondria are a major source of paraquat-induced reactive oxygen species production in the brain. *J Biol Chem.* 2007;282:14186–93.
28. Bonne-Barkay D, Reaney SH, Langston WJ, Di Monte DA. Redox cycling of the herbicide paraquat in microglial cultures. *Brain Res Mol Brain Res* 2005; 134:52–6.
29. Adam A, Smith LL, Cohen GM. An assessment of the role of redox cycling in mediating the toxicity of paraquat and nitrofurantoin. *Environ Health Perspect.* 1990;85:113–7.
30. Zhao F, Wang W, Wang C, et al. Mfn2 protects dopaminergic neurons exposed to paraquat both in vitro and in vivo. *Biochim. et biophys. acta. Mol. Basis Disease.* 2017;6:1359–1370.
31. Cai Z, Zheng F, Ding Y, et al. Nrf2 – regulated miR-380-3p blocks the translation of Sp3 protein and its mediation of paraquat – induced toxicity in mouse neuroblastoma N2a cells. *Toxicol. Sci.* 2019;171(2):515–529.
32. Cocheme HM, Murphy MP. Complex is the major site of mitochondrial superoxide production by paraquat. *J Biol Chem.* 2008;283:1786–89.
33. Costantini P, Petronilli V, Colonna R, Bernardi P. On the effects of paraquat on isolated mitochondria. Evidence that paraquat causes opening of the cyclosporin A-sensitive permeability transition pore synergistically with nitric oxide. *Toxicology.* 1995;99:77–88.
34. Tawara T, Fukushima T, Hojo N, Isobe A, Shiwaku K, Setogawa T, et al. Effects of paraquat on mitochondrial electron transport system and catecholamine contents in rat brain. *Arch Toxicol* 1996;70:585–9.
35. Bus JS, Aust SD, Gibson JE. Paraquat toxicity: proposed mechanism of action involving lipid peroxidation. *Environ Health Perspect.* 1976;16:139–46.
36. Yamada K, Fukushima T. Mechanism of cytotoxicity of paraquat. II. Organ specificity of paraquat-stimulated lipid peroxidation in the inner membrane of mitochondria. *Exp Toxicol Pathol* 1993;45:375–80.
37. Kurisaki E. Lipid peroxidation in human paraquat poisoning. *J Toxicol Sci.* 1985;10:29–33.
38. Sun Y, Zheng J, Xu Y, Zhang X. Paraquat-induce inflammatory response of microglia through HSP60/TLR4 signaling. *Hum. and Exp. Toxicol.* 2018;37(11):1161–1168.
39. Xu G, Wang X, Yu H, Wang C, et al. Beclin 1, LC3 and p62 expression in paraquat-induced pulmonary fibrosis. *Hum. and Exp. Toxicol.* 2019;38(7):794–802.
40. Rasooli R, Pourgholamhosein F, Kamali Y. Combination Therapy With Pirfenidone plus Prednisolone Ameliorates Paraquat-Induced Pulmonary Fibrosis. *Inflammation* 2018;41(1):134–142.
41. Pourgholamhosein F, Rasooli R, Pournamdari M, et al. Pirfenidone protects against Paraquat-Induced lung injury and fibrosis in mice by modulation of Inflammation, oxidative stress, and gene expression. *Food and Chem. Toxicol.* 2018;112:39–46.
42. Fowler BA, Brooks RE. Effects of the herbicide paraquat on the ultrastructure of mouse kidney. *Am J Pathol* 1971;63:505–20.
43. Roberts DM, Wilks MF, Roberts MS, Swaminathan R, Mohamed F, Dawson AH, et al. Changes in the concentrations of creatinine, cystatin C and NGAL in patients with acute paraquat self-poisoning. *Toxicol Lett* 2011;202:69–74.
44. Matsumori H, Matsumoto T, Ishikawa H. Acute toxic effects of paraquat on ultrastructure of rat liver. *Acta Pathol Jpn.* 1984;34:507–18.
45. Gao x, Wang WZ, Xiao Qm, Qix N, et al. Correlation between neutrophil gelatinase-associated lipocalin and soluble CD14 subtype on the prognosis evaluation of acute paraquat poisoning patients. *Hum. and Exp. Toxicol.* 2020;39(4):402–10.
46. Gao Y, Guo S, Wang Y, Yu S, et al. Lymphocyte and its CD4+ and CD8+ subgroup changes after paraquat poisoning. *Hum. and Exp. Toxicol.* 2019;38(9):1024–1030.
47. Li H, Zhu Q, Wang S, et al. Paraquat exposure delays stem progenitor leydig cell regeneration in the adult rat testis. *Chemosphere* 2019;231:60–71.
48. Moyano P, Sanjuan J, Garcia J, et al. Primary hippocampal estrogenic dysfunction induces synaptic proteins alteration and neuronal cell death after single and repeated paraquat exposure. *Food and Chem. Toxicol.* 2020;136:110–111.
49. Eddleston M, Phillips MR. Self poisoning with pesticides. *BMJ.* 2020;328:42–4.

**ДО ОБҐРУНТУВАННЯ ПЕРЕЛІКУ НЕБЕЗПЕЧНИХ ВИСОКОТОКСИЧНИХ ХІМІЧНИХ РЕЧОВИН,
ЯКІ ПІДЛЯГАЮТЬ ОСОБЛИВОМУ КОНТРОЛЮ ЩОДО ОБІГУ, ЗБЕРІГАННЯ, ВИКОРИСТАННЯ ТА УТИЛІЗАЦІЇ**

Частина III (дипіридилові гербіциди паракват і дикват)

М.Г. Проданчук¹, Г.М. Балан¹, О.П. Кравчук¹, П.Г. Жмілько¹, І.М. Максимчук², Н.П. Чермних¹
¹Державне підприємство «Науковий центр превентивної токсикології, харчової та хімічної безпеки
 імені академіка Л.І. Медведя Міністерства охорони здоров'я України», м. Київ, Україна
²Національна поліція України, м. Київ, Україна

РЕЗЮМЕ. Мета. Виділити групу високотоксичних хімічних речовин, які за останні десятиліття найчастіше використовуються в умисних кримінальних та суїцидальних інцидентах, диверсійних і терористичних актах, обіг, зберігання, використання та утилізацію яких потрібно особливо прискіпливо контролювати правоохоронним органам. У даній частині статті йдеться про дипіридилові гербіциди паракват і дикват.

Матеріали та методи. Аналітичний огляд наукових публікацій виконаний з використанням реферативних баз даних наукових бібліотек PubMed, Medline і текстових баз даних наукових видавництв Elsevier, PubMed, Central, BMJ group та інших VIP-баз даних. Застосовано методи системного, порівняльного та контент-аналізу.

Результати та висновки. Аналітичний огляд літературних даних досліджень, проведених у ДП «Науковий центр превентивної токсикології, харчової та хімічної безпеки імені академіка Л.І. Медведя МОЗ України», продемонстрував, що високотоксичні дипіридилові гербіциди паракват і дикват можуть становити загрозу життю і здоров'ю людини. Останнім часом, зокрема понад чверть сторіччя, вони стали справжньою зброєю в руках злочинців, кримінальних елементів і терористів у всьому світі. Не можна замовчувати й суїцидальні інциденти, які також мають місце поряд з умисними кримінальними, терористичними та диверсійними актами. На основі аналізу токсичності, клінічних та морфологічних проявів інтоксикації за дії цих хімічних речовин, враховуючи різні шляхи надходження до організму, обґрунтовано необхідність внесення їх до Переліку особливо небезпечних хімічних речовин, обіг яких, зберігання, використання та утилізація потребують більш жорсткого контролю правоохоронних органів.

Ключові слова: дипіридилові гербіциди, паракват, дикват, ризик для здоров'я, гострі отруєння.

**К ОБОСНОВАНІЮ ПЕРЕЧНЯ ОПАСНЫХ ВЫСОКОТОКСИЧНЫХ ХИМИЧЕСКИХ ВЕЩЕСТВ, ТРЕБУЮЩИХ
ОСОБОГО КОНТРОЛЯ ЗА ИХ ОБОРОТОМ, ХРАНЕНИЕМ, ИСПОЛЬЗОВАНИЕМ И УТИЛИЗАЦИЕЙ**

Часть III (дипиридиловые гербициды паракват и дикват)

Н.Г. Проданчук¹, Г.М. Балан¹, А.П. Кравчук¹, П.Г. Жмілько¹, И.Н. Максимчук², Н.П. Чермных¹
¹Государственное предприятие «Научный центр превентивной токсикологии, пищевой и химической
 безопасности имени академика Л.И. Медведя Министерства здравоохранения Украины», г. Киев, Украина
²Национальная полиция Украины, г. Киев, Украина.

РЕЗЮМЕ. Цель. Выделить группу высокотоксичных химических веществ, которые за последние десятилетия чаще всего используются в преднамеренных криминальных и суицидальных инцидентах, диверсионных и террористических актах, оборот, хранение, использование и утилизация которых требуют особенно жесткого контроля правоохранительных органов. В данной части статьи речь идет о дипиридиловых гербицидах – параквате и диквате.

Материалы и методы. Аналитический обзор научных публикаций выполнен с использованием реферативных баз данных научных библиотек PubMed, Medline и текстовых баз данных научных издательств Elsevier, PubMed, Central, BMJ group и других VIP-баз данных. Применены методы системного, сравнительного и контент-анализа.

Результаты и выводы. На основании обзора литературы и исследований, проведенных в ГП «Научный центр превентивной токсикологии, пищевой и химической безопасности имени академика Л.И. Медведя МЗ Украины» показано, что высокотоксичные дипиридиловые гербициды паракват и дикват представляют угрозу жизни и здоровью человека. В последнее время, в частности более четверти века, они стали настоящим оружием в руках преступников, криминальных элементов и террористов во всем мире. Нельзя замалчивать и суицидальные инциденты, которые также имеют место наряду с умышленными уголовными, террористическими и диверсионными актами. На основе анализа токсичности, клинических и морфологических проявлений этих химических веществ, учитывая различные пути поступления в организм, обоснована необходимость внесения их в Перечень особо опасных химических веществ, оборот которых, хранение, использование и утилизация требуют более жесткого контроля правоохранительных органов.

Ключевые слова: дипиридиловые гербициды, паракват, дикват, риск для здоровья, острые отравления.

Received 04/26/2021